

Figure 3 Cross-section of the eye

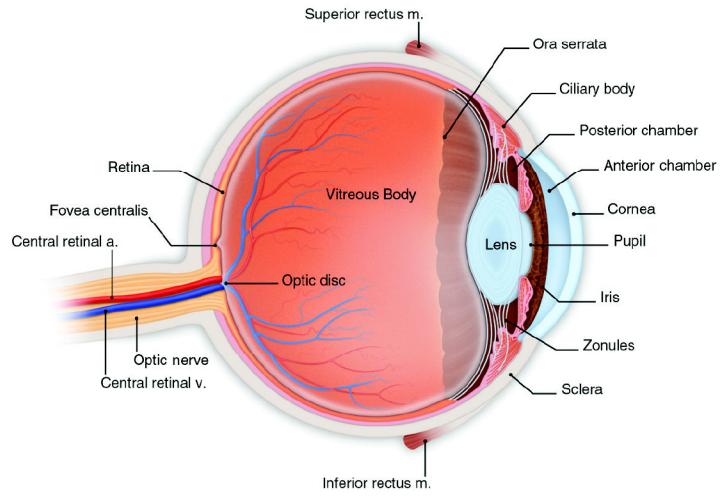


Figure 4 Normal fundus

